Letter to the Editor / *Editöre Mektup*

DOI: 10.5578/ced.20260308 • *J Pediatr Inf 2026;20(3):e230-e232*

Concurrent Varicella and Scarlet Fever Complicated by Pyomyositis

Eş Zamanlı Suçiçeği ve Kızıl Hastalığına Bağlı Gelişen Piyomiyozit: Nadir Bir Olgu Sunumu

Meral Bülbül[1](İD), Oktay Perk [2](İD), Belgin Gülhan[1](İD), Özlem Özkale Yavuz[3](İD), Gülsüm İclal Bayhan[4](İD)

[1] *Department of Pediatric Infectious Diseases, Ankara Bilkent City Hospital, Children's Hospital, Ankara, Türkiye*
[2] *Department of Pediatric Intensive Care, University of Health Science, Ankara Bilkent City Hospital, Ankara, Türkiye*
[3] *Department of Pediatric Radiology, University of Health Science, Ankara Bilkent City Hospital, Ankara, Türkiye*
[4] *Department of Pediatric Infectious Diseases, Ankara Yıldırım Beyazıt University, Faculty of Medicine, Ankara, Türkiye*

Cite this article as: Bülbül Öztoprak M, Perk O, Gülhan B, Özkale Yavuz Ö, Bayhan Gİ. Concurrent varicella and scarlet fever complicated by pyomyositis. J Pediatr Inf 2026;20(3):e230-e232.

Dear Editor,

Varicella has been identified as a major risk factor for invasive *Streptococcus pyogenes* infections, with reported complications including cellulitis, necrotizing fasciitis, pyomyositis, pneumonia, empyema, endocarditis, and sepsis (1,2). Herein, we report a pediatric case of pyomyositis complicating scarlet fever superimposed on an active varicella infection.

A six-year-old boy, previously vaccinated according to the national immunization schedule including a single dose of varicella vaccine, presented to an outside facility with a vesicular rash that began on the head and neck and subsequently spread over the entire body, leading to a diagnosis of varicella. His history revealed fever and rash for the past four days, with the onset of pain originating from the axillary region and radiating to the neck over the preceding two days. His sibling had experienced varicella two weeks earlier. The patient was referred to our hospital due to a progressive lesion on the neck and chest. On physical examination, there were vesicular lesions in various stages of crusting consistent with varicella. In addition, hyperemic maculopapular rashes that blanched on pressure were observed on the trunk and neck, as well as on the arms and legs, with a positive sandpaper-like texture (Figure 1A). Pastia's lines were noted in the abdominal and inguinal folds (Figure 1B,C). An erythematous skin lesion extending from the right axillary region toward the midline of the sternum was present, accompanied by localized warmth, swelling, and marked tenderness on palpation. The patient experienced severe pain on the right shoulder and neck movements, rendering him unable to lift his arm or turn his neck. *S. pyogenes* was detected in a respiratory PCR test performed on an oropharyngeal swab sample. The patient was diagnosed with concurrent varicella and scarlet fever complicated by secondary cellulitis and pyomyositis, and treatment with ceftriaxone, clindamycin, and acyclovir was initiated.

Laboratory tests revealed the following: leukocytes 23.94 $\times 10^3$/µL, neutrophils 20.79 $\times 10^3$/µL, lymphocytes 2.05 $\times 10^3$/µL, hemoglobin 12.8 g/dL, platelets 226.000/µL, and C-reactive protein 207 mg/L. Follow-up examinations performed on the same day showed that the painful, erythematous cellulitic lesion had markedly progressed within hours, extending be-

Correspondence Address/Yazışma Adresi
Meral Bülbül
Department of Pediatric Infectious Diseases, Ankara Bilkent City Hospital, Children's Hospital, Ankara, Türkiye
E-mail: drmeraloztoprak@hotmail.com

Received: 02.09.2025 **Accepted:** 27.10.2025
Available Online Date: 12.10.2026

This work is licensed under the Creative Commons Attribution-NonCommercial-ShareAlike 4.0 International License.
Data Sharing Statement: The data that support the findings of this study are available from the corresponding author upon reasonable request.
©Copyright 2026 by Pediatric Infectious Diseases and Immunization Society. Available online at www.cocukenfeksiyon.org

yond the pectoral region toward the midline of the sternum and further inferiorly. The patient was transferred to the intensive care unit. No pathology was detected on ultrasonography of the right shoulder joint. Neck and thoracic magnetic resonance imaging (MRI) revealed inflammatory, heterogeneous soft tissue thickening measuring up to 15 mm in thickness, with signal intensities and contrast enhancement consistent with edema and inflammation. These findings extended from both inferior cervical regions, the right axillary and anterior axillary areas, and the anterior, lateral, and posterior walls of the right chest, inferiorly to the lateral and posterior abdominal wall, and posteriorly to the dorsal region. The process involved the skin and subcutaneous tissues, as well as intermuscular planes between the chest and abdominal wall muscles, predominantly affecting the pectoralis, intercostal, and latissimus dorsi muscles (Figure 1D). The MRI findings supported the diagnosis of pyomyositis. Blood cultures remained sterile. As the varicella lesions crusted, acyclovir was discontinued on day seven. During follow-up, the patient's joint pain and skin lesions resolved completely.

Secondary bacterial infections in varicella are most caused by *S. pyogenes* and *Staphylococcus aureus*. While there are numerous reports describing cutaneous complications due to *S. pyogenes* infection, cases of concurrent varicella and scarlet fever have been rarely documented (3-5). Reported complications of concurrent varicella and scarlet fever include empyema, cellulitis, severe swelling of the inguinoscrotal region, and widespread monomorphic vesicular eruptions superimposed on the erythema of scarlet fever (3-5). Streptococcal pyomyositis, necrotizing pyomyositis, and necrotizing fasciitis

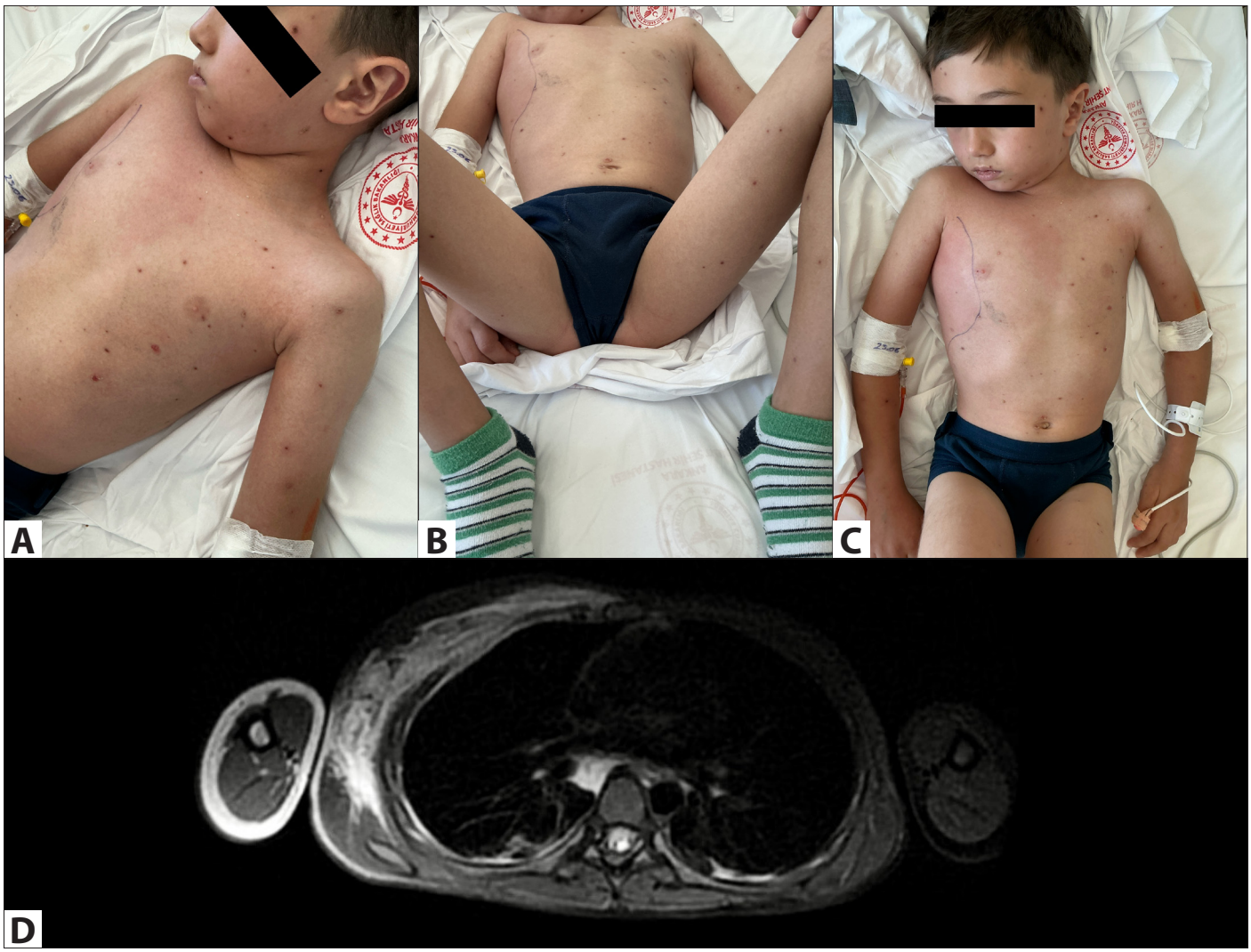

Figure 1. A) Polymorphic varicella rash accompanied by a maculopapular scarlet fever rash and an erythematous lesion extending from the right axillary region to the midline of the sternum; **B-C)** Pastia's lines in the lower abdominal area and in the gluteal folds; **D)** MRI demonstrating inflammatory, heterogeneous soft tissue thickening with signal abnormalities and contrast enhancement consistent with edema and inflammation involving the skin and subcutaneous tissues.

are among the rare but severe complications of varicella, and their management may require fasciotomy, abscess drainage, and hyperbaric oxygen therapy (2). In the present case, we aimed to highlight that varicella and scarlet fever can, although rarely, occur simultaneously and may be complicated by pyomyositis. In countries such as Türkiye, where only a single dose of varicella vaccine is administered, the introduction of a routine second dose could contribute to the prevention of breakthrough varicella infections and associated complications.

References

1. *Schwidetzky J, Heininger U, Salzmann M, Neuhaus TJ, Buettcher M. Clinical outcomes and severe complications of hospitalised children and adolescents with varicella in central Switzerland: A retrospective observational study. Swiss Med Wkly 2025;155:3962. https://doi.org/10.57187/s.3962*
2. *Mills WJ, Mosca VS, Nizet V. Orthopaedic manifestations of invasive group A streptococcal infections complicating primary varicella. J Pediatr Orthop 1996;16:522-8. https://doi.org/10.1097/01241398-199607000-00021*
3. *Friedman MA, Klein JD, Eppes SC. Inhibition of the scarlet fever exanthem in concurrent varicella and group A streptococcus infection. Clin Infect Dis 1993;16:286-7. https://doi.org/10.1093/clind/16.2.286*
4. *Oyake S, Ohi T, Koga M. A case of varicella complicated by cellulitis and scarlet fever due to Streptococcus pyogenes. J Dermatol 2000;27:750-2. https://doi.org/10.1111/j.1346-8138.2000.tb02272.x*
5. *Egan CA, O'Reilly MA, Vanderhooft SL, Rallis TM. Acute generalized varicella zoster in the setting of preexisting generalized erythema. Pediatr Dermatol 1999;16:111-2. https://doi.org/10.1046/j.1525-1470.1999.00026.x*